Jpn J Endourol ESWL (2003) 16 : 108－114

Original Article

Toyoaki Uchida Hideyasu Tsumura Hideyuki Yamashita Masayuki Katsuta Daisuke Ishii
Takefumi Satoh Asako Ohkawa Toru Hyodo Narendra T Sanghvi

Transrectal high-intensity focused ultrasound for treatment of patients with stage T1b-2N0M0 localized prostate cancer：A preliminary report

Japanese Journal of Endourology
and ESWL Vol.16 No.1 2003別刷
日本Endourology. ESWL学会

Jpn J Endourol ESWL (2003) 16 : 108－114

Original Article

Toyoaki Uchida Hideyasu Tsumura Hideyuki Yamashita Masayuki Katsuta Daisuke Ishii
Takefumi Satoh Asako Ohkawa Toru Hyodo Narendra T Sanghvi

Transrectal high-intensity focused ultrasound for treatment of patients with stage T1b-2N0M0 localized prostate cancer : A preliminary report

Abstract We evaluated the efficacy and safety of a high-intensity focused ultrasound (HIFU) for localized prostate cancer. We performed 41 HIFU treatments in 30 patients with localized prostate cancer using Sonablate-200™. Demographics of these patients are (mean ± SD) : age 71.9 ± 6.9 years, prostate volume 28.1 ± 12.1 ml, PSA 10.81 ± 5.83 ng/ml. Gleason scores: 2-4, 5-7 and 8-10 in 9, 20 and 1 patients respectively. One, two and three HIFU treatment sessions were performed in 20, 9 and 1 patient, respectively. Mean duration of treatment was 2 hrs 50 min (33-356 min). The clinical outcome of 30 patients followed for at least 6 months (mean 14.7 months) is as follows. Ninety-seven % (29/30) of patients demonstrated complete response (CR). Failure was identified as any positive postoperative prostate biopsy regardless of the PSA concentration or successive elevation of PSA on three examinations with a velocity≧ 0.75 ng/year in patients with negative biopsy. Follow-up sextant biopsies showed 100% (30/30) of the patients to be cancer free. One patient underwent transurethral resection of the prostate for prolonged urinary retention, one patient developed a rectourethral fistula and 7 patients developed urethral stricture. Early follow-up would suggest that transrectal HIFU therapy could be used to ablate localized prostate cancer with an acceptable incidence of adverse events accompanied by a relatively high CR rate and the ability to deliver repeated HIFU treatments.

Key words high-intensity focused ultrasound, transrectal, localized prostate cancer

T Uchida : Department of Urology, Tokai University Hachioji Hospital 1838, Ishikawa-machi, Hachioji, Tokyo 192-0032, Japan
TEL 0426-39-1111, FAX 0426-39-1144
E-mail uchida.toyoaki@hachioji-hosp.tokai.ac.jp
H Tsumura · H Yamashita · M Katsuta · D Ishii · T Satoh · A Ohkawa · T Hyodo : Department of Urology, Kitasato University School of Medicine, Sagamihara, Kanagawa, Japan
NT Sanghvi : Focus Surgery, Inc., Indianapolis, Indiana, USA
Received ; 4 Oct. 2002 ; accepted in final form 5 Nov. 2002

Introduction

Prostate cancer is the leading malignancy in men and the second leading cause of death due to cancer in the United States.[1] In recent years, the rate of prostate cancer in Japanese males is also increasing. The death rate of prostate cancer per 100,000 men in 1985 increased from 4.5 to 11.4 in 1999 in Japan.[2] Prostate cancer is treated in various ways, depending in the severity of the condition, age of the patient, staging, Gleason score and serum prostate-specific antigen (PSA) levels. Despite excellent 5- to 10-year survival rates after radical prostatectomy for organ-confined disease, surgery is associated with significant morbidity, such as blood loss with transfusion-related complications, impotence in 30% to 70% of cases, and stress incontinence in up to 10% of patients.[3-5] In addition, surgical intervention is not typically considered for patients whose life expectancy is less than 10 years. Although the immediate complication rate is lower with radiation therapy, impotence, incontinence, radiation proctitis, and cystitis are frequent late sequelae.[6] Moreover, it has been shown that over 50% of patients have elevated serum levels of PSA.[7]

Recently, a number of alternative minimally invasive treatments have been developed to treat localized prostate cancer. Brachytherapy, cryosurgical ablation of the prostate, three-dimensional conformal radiotherapy and laparoscopic radical prostatectomy have been applied, but a definitive cure cannot always be achieved, and generally the treatment cannot be repeated in cases of local recurrence.[6-11] Since 1992 and 1999, we have been treating benign prostatic hyperplasia and localized prostate cancer with transrectal high-intensity focused ultrasound (HIFU).[12,13] HIFU delivers intense ultrasound energy, with consequent heat destruction of tissue at a specific focal distance from the probe without damage to tissue in the path of the ultrasound beam. We report herein our clinical experience treating 30 patients with stage T1b-2N0M0 localized prostate cancer by transrectal HIFU.

Patients and methods

1. HIFU equipment

For this study, we used a modified second-generation device called the Sonablate-200™ (Fig. 1, Focus Surgery, Inc., Indianapolis, IN, USA). The Sonablate-200™ is a computer-controlled machine intended to provide HIFU treatment for benign prostatic hyperplasia and localized prostate cancer. A treatment module includes the ultrasound power generator, multiple transrectal probes of different focal depth, the probe positioning system, and a cooling system. The transrectal HIFU probes use proprietary transducer technology with low-energy ultrasound (4 MHz) for imaging of the prostate and for delivery of high-energy ablative pulses (site intensity, 1300-2200 W/cm^2). The single piezoelectric crystal alternates between high-energy ablative (1-4 seconds) and low-energy (6-12 seconds) ultrasound for a total cycle of 7 to 16 seconds.

Before starting treatment, the operator obtains longitudinal and transverse sonograms (transrectal ultrasound; TRUS) of the prostate and selects the prostate tissue volume to be ablated by setting cursors on these images. The probe houses a computer-controlled positioning system that directs each ablative pulse to the targeted region of the prostate. Each discrete high-energy focused ultrasonic pulse ablates a volume of $2 \times 2 \times 10$ mm^3 in a single beam for 2.5- and 4.5-cm focal length probes and $3 \times 3 \times 10$ mm^3 of tissue in a split beam for 3.0-, 3.5- and 4.0-cm focal length probes.[14] For a single beam, operation power density is set by the computer using tissue depth measurements. In the split beam mode, total acoustic power (TAP) is initially set at 24, 35 and 37 watts for 3.0-, 3.5- and 4.0-cm focal length probes, respectively. The individual focal lesion produces almost instantaneous coagulative necrosis of tissue due to a temperature rise of 80° to 95℃ in the

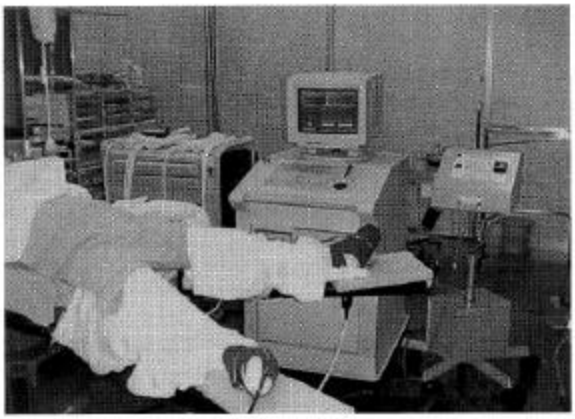

Fig. 1 The Sonablate-200™ type device consists of an operator's console, imaging monitor, transrectal probe and continuous cooling system.

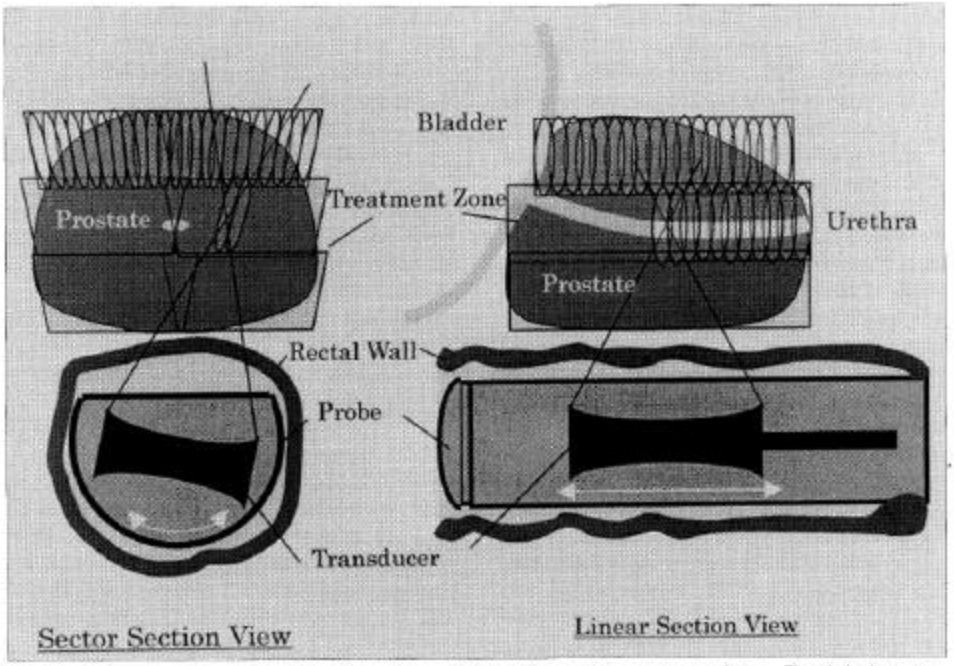

Fig. 2 The computer-controlled transducer ablates the entire prostate tissue. Focal lesions are overlapped in linear rows (left) at each of the lateral sector positions (right) to create a volume lesion.

focal zone.[14), 15)] Under computer control, the ultrasound beam is steered mechanically to produce consecutive lesions in a manner such that all focal lesions overlap laterally and longitudinally to ensure necrosis of the entire targeted prostate volume (Fig. 2). A semi-automatic cooling device was used in the first 18 HIFU treatments to maintain the transrectal temperature below 37℃ and thereafter an automatic cooling device has been used during treatment to maintain a constant baseline temperature below 20℃ in the transrectal probe, which helps to prevent thermal injury of the rectal mucosa.

2. HIFU procedure

Patient preparation included a cleansing enema, and all patients were anesthetized by epidural anesthesia and intravenous sedation. A condom was placed over the probe and degassed water was used to inflate the condom that was covered with ultrasound gel for close coupling of the ultrasound probe to the rectal wall. The patient was placed in the lithotomy position and the probe inserted manually into the rectum. A 16F Foley balloon catheter was inserted into the bladder to identify the urethra and bladder neck and 100-150 mL saline solution was introduced into the bladder. Probes with focal lengths of 2.5, 3.0, 3.5, 4.0 and 4.5 cm were used according to the size of the prostate as determined by TRUS, with larger glands requiring longer focal lengths. The probe was fixed in position by an articulating arm attached to the operating table. After selecting the treatment region of the prostate from the verumontanum to the bladder neck, the treatment was started. The balloon catheter was removed just before HIFU treatment. The treatment continued layer by layer (10 mm thick) from the apex to the base. Usually, three successive target areas (anterior, mid-part and base) were defined to treat the whole prostate (Fig. 2). The thermal effect of transrectal HIFU is extremely precise with a sharp temperature gradient and fall-off characteristics.[14),15)] Therefore, in cases where the cancer is unilateral and preservation of potency is considered mandatory by the patient, the contralateral neurovascular bundle could be excluded from the treatment. After completing treatment, a transurethral balloon catheter, or percutaneous cystostomy using a 16F or 12F Foley balloon catheter was inserted into the bladder.

3. Patient recruitment

As a rule, the inclusion criteria for treatment were patients with stage T 1 b- 2 N0M0 localized prostate cancer, prostate volumes less than 50 mL, and a serum PSA level less than 25 ng/ml. Patients with anal stricture were excluded from the study.

All patients were fully informed of the details of this treatment and provided written consent preoperatively. All patients underwent a digital rectal examination and measurement of serum PSA using an AxSYM PSA assay (Abbott Laboratories, Abbott Park, IL, USA). TRUS, computed tomography (CT) and/or magnetic resonance imaging (MRI) of the pelvic cavity including the prostate were performed to detect evidence of carcinoma and intrapelvic lymph node metastasis. A chest x-ray, abdominal ultrasound or CT of the liver, and bone scans were performed to detect distant metastasis in all patients. All enrolled patients had negative preoperative metastasis in the lung, liver, bone and intrapelvic lymph nodes. All patients showed evidence of adenocarcinoma by prostate biopsy. The TNM staging system was used for clinical staging.[16)]

In total, 30 patients with a mean age of 71.9 ± 6.9 years (range, 57-86 years) were included in the trial: 1 patient with clinical stage T 1 b, 16 patients with clinical stage T 1 c, 11 patients with clinical stage T 2 a, and 2 patients with clinical stage T 2 b. The mean PSA concentration and prostate volume were 10.81 ± 5.83 ng/mL (range, 3.39-21.80 ng/mL) and 28.1 ± 12.1 ml (range, 13.2-68.8 ml), respectively. The histologic grade was, Gleason sum 3 to 4 in 9 patients, Gleason sum 5 to 7 in 20 patients, and Gleason sum 9 in 1 patient. Neoadjuvant hormonal therapy was administrated to 7 patients (mean ± S.D., 3.1 ± 1.3 months; range 1.5-5.0 months). All these patients had already received therapy at another hospital prior to HIFU treatment. Hormonal therapy was not continued in any patient after transrectal HIFU ablation.

4. Follow-up and definition of outcome

Patient status and treatment-related complications were followed by all available means, including periodic patient visits and self-administered questionnaires regarding continence and potency. Serum PSA was usually assayed at day 1, 14, 30 and then every 1 to 3 months during follow-up. A randomized sextant control prostatic biopsy was performed at 6 months or when there was any evidence of biochemical failure. Patients with a rising PSA concentration and a negative prostatic biopsy underwent a bone scan and a CT scan to assess metastatic disease. The mean follow-up period in 30 patients who were followed more than 6 months was 14.7 ± 7.1 months (range, 6 -35 months). Complete response (CR) was categorized as any response other than Failure, which was identified as any positive postoperative prostate biopsy regardless of the PSA concentration or three successive tests showing elevation of PSA with a velocity ≧0.75 ng/year in patients with negative biopsy.[17)]

Results

The prostate was treated by 1 (n=20 patients), 2 (n= 9 patients) or 3 (n= 1 patient) sessions for a total of 41 procedures in 30 patients (1.4 sessions/patient). Reasons for repeated HIFU treatments were: 2 patients were selectively treated on the right lobe of the prostate because preoperative prostate biopsy had shown unilateral disease only and 6 patients were retreated because of short on (2 seconds) or long off (8 to 12 seconds) HIFU intervals. In addition, 2 patients required repeated treatment because of a larger prostate size (37.9 and

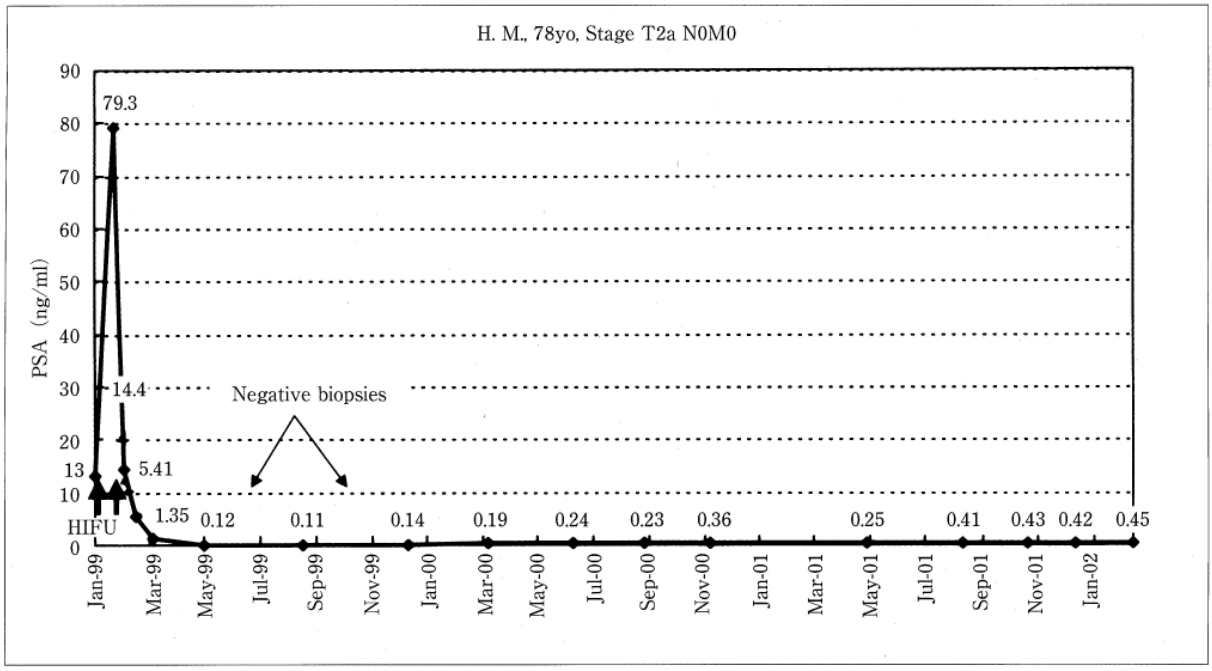

Fig. 3 Changes in serum PSA. Due to the advanced age of this patient and concomitant anticoagulant therapy, he underwent 2 sequential sessions of HIFU instead of radical prostatectomy. The estimated prostatic volume on TRUS decreased from 37.0 to 5.5 mL at pre- and 10 months post-treatment, respectively. Follow-up biopsies demonstrated intense coagulation necrosis at 2 months and extensive fibrotic tissue containing occasional atrophic glands without viable cancer cells at 6 and 10 months postoperatively. H, HIFU treatment

50.6 mL) (Fig. 3) and 1 patient was retreated due to technical difficulty with the device. Among 41 HIFU treatments, 4, 3, 1 and 1 different focal length probes were used in 3, 9, 27 and 2 cases, respectively and probe changes was needed 2.2 times per patient. The mean operating time was 2 hours 50 minutes (range, 55 minutes to 356 minutes). The mean hospitalization stay and postoperative urinary catheterization time were 6.5 ± 3.5 days (range, 3-20 days) and 9.7 ± 10.7 days (range, 1-55 days), respectively. A gradual reduction in prostate volume occurred in all patients. The gland size decreased from an initial mean volume of 28.1 ± 12.1 mL (range, 13.2-68.8 mL) to a final mean volume of 16.1 ± 9.4 mL (range, 4.4-50.3 mL) on average 7.3 (range, 3-23) months interval.

Ninety-seven % (29/30) of patients demonstrated a complete response (CR). Serum PSA nadirs occurred within 1-2 month postoperatively. Sixty% (18/30), 27% (8/30), 10% (3/30) and 3% (1/30) of patients had PSA nadirs of ≦0.50 ng/ml, 0.51-1.00 ng/ml, 1.01-2.00 ng/ml and 2.01-4.00 ng/ml, respectively. Follow-up sextant biopsies showed that 100% (30/30) of the patients had become cancer free. The main pathological findings of the prostate biopsy at 6 months after the procedure showed coagulation necrosis and fibrosis.

Acute urinary symptoms such as frequency, urgency and difficulty in urination were common during the first 2 months after HIFU treatment. The symptoms proved to be transitory and were easily managed by medical treatment such as α-blockers and/or painkiller such as Voltaren® suppository. Urethral ballon catheter in all patients was removed 1 to 2 day postoperatively but the catheter was re-placed in patients who could not urinate spontaneously and removal of the catheter was attempted every 1 to 2 weeks thereafter. Rectourethral fistula was noted in 1 patient two months after the second HIFU procedure. He was successfully treated by colonoscopic surgery with paste and direct suture of the fistula under transient cystostomy. Urethral stricture occurred in 7 patients who were all treated by internal urethrotomy with a cold-knife as an outpatient procedure 3-6 months postoperatively. One patient opted for transurethral resection of the prostate because of persistent urinary retention at 22 days postoperatively. The pathological finding of the resected tissue showed coagulative necrosis. There was no incontinence observed during follow-up. FACT-P was decreased from 12.8 ± 2.5 to 11.8 ± 3.2 (16 patients) 6 months postoperatively but there was no significant difference noted. Postoperative impotence was noted in 5 (33%) of 15 patients when assessed by self-administered questionnaire.

Discussion

In 1995, Madersbacher et al. reported the effect of

Table 1 Clinical outcome.

Report	No. patients	CR*	Failure	Mean Follow-up (range)
Gelet et al.[17]	82	62%	38%	17.6mo (3-68mo)
Current study	30	97%	3%	14.7mo (6-35mo)

*CR : any response other than Failure which was identified by any positive postoperative prostate biopsy regardless of the PSA concentration or three successive elevations of PSA with a velocity ≧0.75 ng/year with negative biopsy.

HIFU (using Sonablate™ 200) in an experimental study of 10 cases of histologically demonstrated, hypoechoic and palpable, localized prostate cancer.[15] In this study, only the focal region of the prostate showing a hypoechoic pattern on TRUS was treated by HIFU. The organs were subsequently removed. In 2 cases, the entire carcinoma had been ablated by the procedure, but in the other 8 cases, a mean of 53% of cancer tissue had been destroyed. However, this study was discontinued primarily as it took 8 - 9 hours to treat a 20 ml volume of prostate tissue. In January 1999, we began HIFU treatment for localized prostate cancer using a modified Sonablate-200™ device. Major improvements in our device included: (1) a reduction in HIFU exposure cycle from 16 seconds (4 on/12 off) to 9 seconds (3 on/6 off) which reduced treatment time by 44%, and (2) the introduction of a novel transducer and electronics that splits a single ultrasound beam into multiple beams (termed "split beam") to cover a larger tissue volume per exposure. The single beam had a focal region of 2 × 2 ×10 mm (volume = 40mm^3) while the split beam focal region is 3 × 3 ×10 mm (volume = 90mm^3) which further reduced treatment time by about 50%.[13),14] These developments dramatically shortened the treatment time for a 25 ml prostate gland from 6 hours to 2 hours.

In 1996, Gelet et al. reported a preliminary experience with HIFU using Ablatherm prototype 1.0 (EDAP-Technomed, Lyon, France) for treating localized prostate cancer.[18] They later summarized their clinical results in which a complete response was obtained in 56% of the patients with no residual cancer and a PSA less than 4 ng/ml. Biochemical failure (no residual cancer and a PSA greater than 4 ng/ml), biochemical control (residual cancer and a PSA less than 4 ng/ml), and failure (residual cancer and a PSA greater than 4.0 ng/ml) were noted in 6%, 18% and 20% of patients, respectively.[19] In 1999, Beerlage et al. reported results of 143 HIFU treatments using the Ablatherm prototype 1.0 and 1.1 in 111 patients with clinical stage T 1 - 3 N0M0 prostate cancer, and PSA less than 25 ng/mL. The first 65 treatments in 49 patients were performed selectively (i.e., a unilateral or bilateral treatment in one or two sessions was performed depending on the findings from TRUS and biopsies) and the second 78 treatments in 62 patients who received treatment of the whole prostate. A complete response (defined as a PSA <4.0 ng/ml and a negative biopsy) was achieved in 60% of the group undergoing whole prostate treatment and in 25% of the selectively treated patients.[20] In our study, two patients who were treated selectively in the right lobe of the prostate for adenocarcinoma identified by a prostate biopsy, showed a gradual elevation of PSA as well as viable cancer cells on a postoperative prostate biopsy. Therefore, a second HIFU treatment was performed on the whole prostate and then PSA level has kept low level as well as negative biopsy. Recently, many means of imaging analyses have been performed to detect prostate cancer, including TRUS, CT, endorectal coil MRI and multiple biopsies of the prostate under TRUS. However, prostate cancer is a multifocal disease and it is not yet possible to determine the sites of microscopic foci of cancer cells by imaging analysis alone. Therefore, the whole prostate must be treated, as the results of this HIFU study and other studies corroborate.

Many response criteria have been applied after radical prostatectomy or irradiation therapy including brachytherapy. To identify progression after radical prostatectomy, some investigators have used the detectable level of PSA, some a single value greater than 0.4 or 0.5 and others 2 consecutive values of 0.2 ng/ml or greater.[21] However, these criteria are not suitable to determine the clinical effect in patients received HIFU. Because, the prostate still remains after HIFU treatment that is similar after radiation therapy. In 1997 the American Society for Therapeutic Radiology and Oncology (ASTRO) determined the biological failure after radiation therapy that is 3 consecutive increases in PSA.[22] Several recent studies of HIFU therapy using Ablatherm devices have demonstrated 73% to 56% complete responses with a negative biopsy and a PSA less than 4.0 ng/ml.[17)-20),23] More recently, Gelet et al. reported the clinical results of HIFU treatment using stricter response criteria.[17] Their criteria for determining failure included any positive biopsy regardless of the PSA concentration or three successive elevations of PSA with a velocity≧0.75 ng/year in patients with negative biopsy. When we summarize our clinical outcome by these strict response criteria, 97% of patients also showed a complete response in the study (Table 1).

About 20% of patients may have seminal vesicle and lymph node involvements in clinical stage T 1 b- 2 N0M0 prostate cancer.[24] In our experience, stage T 1 c- 2 N0M0 localized prostate cancer patients with preoperative PSA less than 25 ng/ml is showed a favorable clinical response up to present. Further experience is required to determine what stages, grades and/or level of PSAs in localized prostate cancer patients are suitable for HIFU.

As a disadvantage of HIFU treatment for localized prostate cancer, limitation of the prostate volume was noted. In our experience, a prostate measuring fifty ml was the limit of the present HIFU device even using a 4.5 cm focal length probe. It is necessary to develop a longer focal length probe to treat prostate volumes over 50 ml volume. Neoadjuvant androgen deprivation ther-

apy may be useful in larger prostates especially since reduction of the target volume may increase the efficacy of the HIFU treatment. In addition, patients with large intraprostatic calcification are not suitable candidates for HIFU. Because tissue calcifications cause reflection of the ultrasound beam which may generate a coagulation necrosis in an unexpected area as well as preventing tissue necrosis anterior to the calcifications.

In our study, postoperative urinary retention was noted in 80% of the patients. Catheterization of patients is required after HIFU treatment and cannot be avoided because of transient edema of the prostate gland. We performed postoperative cystostomy for 3 patients to prevent postoperative urinary retention but these patients showed more prolonged urinary retention (mean; 39.0 days) than patients without cystostomy (mean 7.4 days). Intermittent self-catheterization, transient placement of prostatic stents or TURP after HIFU treatment might solve this problem. A rectourethral fistula occurred in one patient whose rectum was cooled to less than 37℃ by the semi-automatic cooling system. Furthermore, urethral stricture in the prostatic urethra occurred in 7 patients. All strictures were noted at anterior border of the treated lesion near the verumontanum. All these patients were treated by internal urethrotomy and/or periodical bouging with metal sounds. Following TURP after HIFU treatment may be useful to prevent such postoperative urethral stricture.

Generally, radicalism of prostate cancer surgery and preservation of sexual function remain controversial, because postoperative impotence depends on preservation of neuro-vascular bundles that are sometimes involved by tumor invasion. On self-reporting questionnaire, 33% of the patients indicated post-HIFU impotence, we considered this rate lower than that of radical prostatectomy.[3)-5)] Advanced ultrasound guidance system with Doppler may help to preserve neuro-vascular bundles while treating the lesion more accurately. Obviously, further experience is required to confirm this important point.

For many reasons, transrectal HIFU appears highly attractive as a minimally invasive treatment for localized prostate cancer. One of the most favorable advantages is that HIFU therapy can be repeated or added even though patients with local recurrence have already been treated with a radical prostatectomy, cryoablation of the prostate and radiation therapy including brachytherapy. HIFU treatment is minimally invasive, bloodless (no incision), can be performed on an outpatient basis, has a low cost and avoids systemic side effects. These features combined with the optional curative effect are ideal treatment for patients with localized prostate cancer. The small number of patients and the relatively short follow-up period in our series limit our ability to draw any definitive conclusions. The data we present here suggests that HIFU could be a useful treatment option for patients with localized prostate cancer and that it has an acceptable side effect profile that warrants further investigation.

Acknowlwdgment

The authors express their appreciation to Mr. Y. Shimazaki, S. Kagosaki, K. Yamashita and K. Takai for technical assistance.

Refrences

1) Landis SH, Murray T, Bolden S, et al (1999) Cancer statistics, CA Cancer J Clin 49 : 8-31
2) Statistics and Information Department, Minister's Secretariat, Ministry of Health and Welfare, Health and Welfare Statistics Association : Statistical Abstract on Health and Welfare in Japan 2000. Tokyo : Health and Welfare Statistics Association, 2000, p 55
3) Arai Y, Egawa S, Tobisu K, et al (2000) Radical retropubic prostatectomy : time trends, morbidity and mortality in Japan. BJU Int 85 : 287-294
4) Han M, Walsh PC, Partin AW, et al (2000) Ability of the 1992-1997 American Joint Committee on Cancer Staging for prostate cancer to predict progression-free survival after radical prostatectomy for stage T 2 disease. J Urol 164 : 89-92
5) Amling CL, Blute ML, Bergstralh EJ, et al (2000) Long-term hazard of progression after radical prostatectomy for clinically localized prostate cancer : continued risk of biochemical failure after 5 years. J Urol 164 : 101-105
6) Brawer MK (2002) Radiation therapy failure in prostate cancer patients : Risk factors and methods of detection. Rev Urol 4 (supple 2) : S 2 -S11
7) Beard CJ, Lamb C, Buswell L, et al (1998) Radiation-associated morbidity in patients undergoing small-field external beam radiation for prostate cancer. Int J Radiat Oncol Biol Phys 41 : 257-262
8) Schmidt JD, Doyle J, Larison S (1998) Prostate cryoablation : update 1998. CA Cancer J Clin 48 : 239-253
9) Zelefsky MJ, Wallner KE, Ling CC, et al (1999) Comparison of the 5 -year outcome and morbidity of three-dimentional conformal radiotherapy versus transperineal permanent iodine-125 implantation for early stage prostate cancer. J Clin Oncol 17 : 517-522
10) Beerlage HP, Thuroff S, Madersbacher S, et al (2000) Current status of minimally invasive treatment options for localized prostate carcinoma. Eur Urol 37 : 2 -13
11) Guillonneau B, Vallancien G. (2000) Laparoscopic radical prostatectomy : the Montsouris experience. J Urol 163 : 418-422
12) Uchida T, Muramoto M, Kyunou H, et al (1998) Clinical outcome of high-intensity focused ultrasound for treating benign prostatic hyperplasia : preliminary report. Urology 52 : 66-71
13) Uchida T, Sanghvi NT, Gardner TA, et al (2002) Transrectal high-intensity focused ultrasound for treatment of patients with stage T1b-2N0M0 local-

ized prostate cancer : a preliminary report. Urology 59 : 394-399
14) Wu JSY, Sanghvi NT, Phillips MH, et al (1999) Experimental studies of using of split beam transducer for prostate cancer therapy in comparison to single beam transducer. 1999 IEEE Ultrasonics Symposium Proceedings 2 : 1443-1446
15) Madersbacher S, Pedevilla M, Vingers L, et al (1995) Effect of high-intensity focused ultrasound on human prostate cancer in vivo. Cancer Res 55 : 3346-3351
16) International Union Against Cancer. In : Sobin LH, Witterkind CH, editors. TNM classification of malignant tumors. 5th edition, 1997, New York : John Wiley and Sons, Inc, 1997, pp 170-173
17) Gelet A, Chapelon JY, Bouvier R, et al (2000) Transrectal high-intensity focused ultrasound : Minimally invasive therapy of localized prostate cancer. J Endourol 14 : 519-528
18) Gelet A, Chaperon JY, Bouvier R, et al (1996) Treatment of prostate cancer with transrectal focused ultrasound : early clinical experience. Eur Urol 29 : 174-183
19) Gelet A, Chaperon JY, Bouvier R, et al (1999) Local control of prostate cancer by transrectal high intensity focused ultrasound therapy : preliminary report. J Urol 161 : 156-162
20) Beerlage HP, Thüroff S, Debruyne FMJ, et al (1999) Transrectal high-intensity focused ultrasound using the Ablatherm device in the treatment of localized prostate carcinoma. Urology 54 : 273-277
21) Moul JW (2000) Prostate specific antigen only progression of prostate cancer. J Urol 163 : 1632-1642
22) American Society for Therapeutic Radiology and Oncology Consensus Panel (1997) Consensus statement : guidelines for PSA following radiation therapy. Int J Radiat Oncol Biol Phys 37 : 1035-1041
23) Chaussy CG, Thüroff S (2000) High-intensity focused ultrasound in localized prostate cancer. J Endourol 14 : 293-299
24) Partin AW, Kattan MW, Subong EN, et al (1997) Combination of prostate-specific antigen, clinical stage, and Gleason score to predict pathological stage of localized prostate cancer. A multi-institutional update. JAMA 227 : 1445-1451